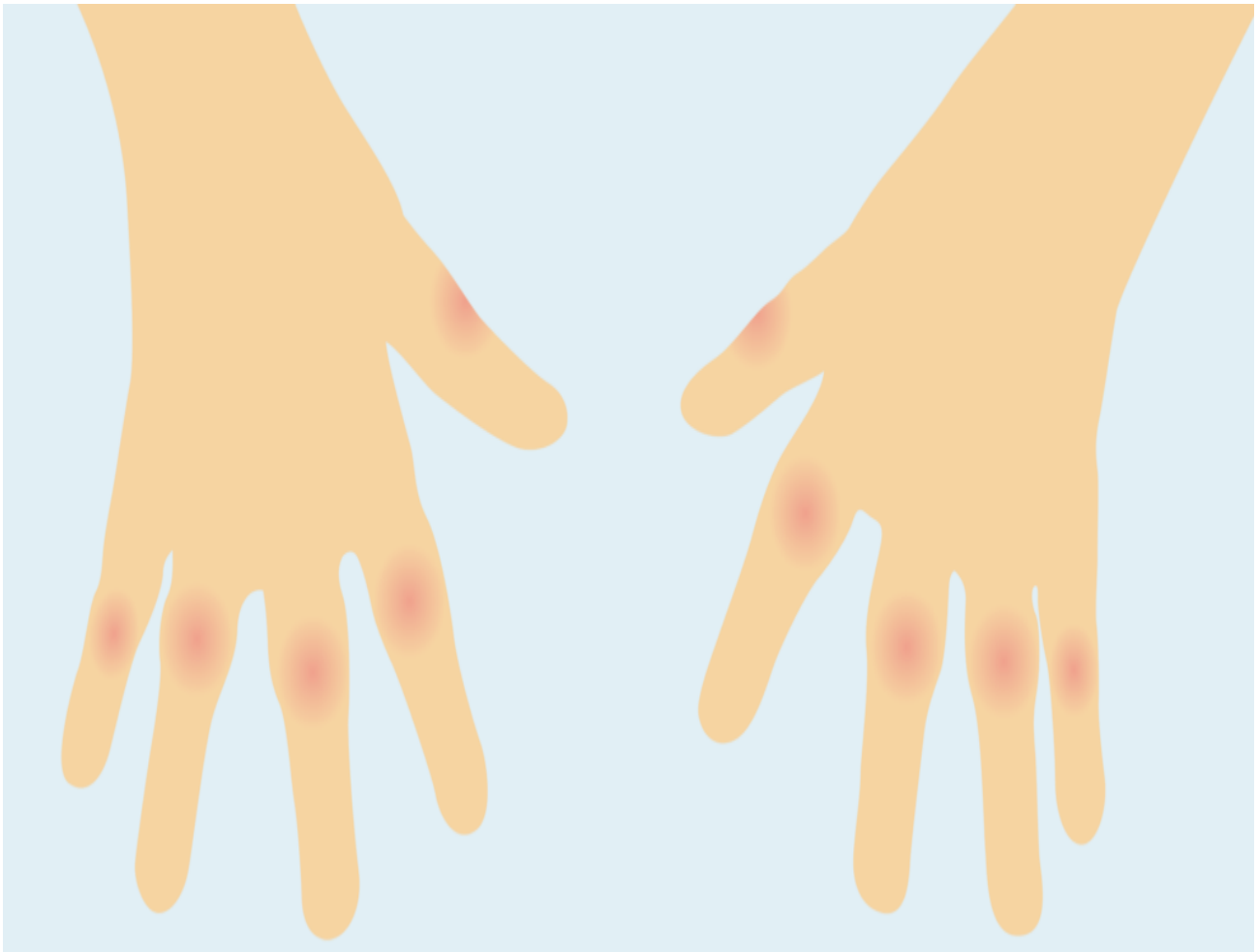


Resource

Rheumatoid nodules

Rheumatoid nodules are firm lumps that appear under the skin in up to 20% of patients with RA. They usually occur overexposed joints that are subject to trauma, such as the finger joints and elbows.

[Print](#)



Rheumatoid nodules are firm lumps that appear subcutaneously (i.e. under the skin) in up to 20% of patients with rheumatoid arthritis. These nodules usually occur overexposed joints that are subject to trauma, such as the fingers joints and elbows, though occasionally they can occur elsewhere such as the back of the heel. They are usually non-tender and only occasionally painful, and very rarely the overlying skin can become infected or even ulcerate. Rarely they can occur in the lungs and vocal

cords.

There is a suggestion that the incidence of rheumatoid nodules is falling (possibly due to the reducing severity of rheumatoid arthritis), but nowadays they are most commonly seen in patients commenced on methotrexate therapy in whom the nodules that develop tend to be small and multiple (micronodules) most commonly around the finger joints. About 8% of patients on methotrexate develop micro-nodules, and we don't really know why. The image with this article shows a severe case of rheumatoid nodules. Micro-nodules are normally slightly smaller, at around 0.5cm across.

Rheumatoid nodules are very firm and are made of inflammatory tissue but under the microscope show intense inflammatory changes that are different from the ones that are found within the joints. This explains why disease-modifying drugs and biological therapies may not reduce the size of the nodules even though they may have an excellent effect on controlling joint disease.

Who develops rheumatoid nodules?

Patients who develop nodules are more likely to be smokers, tend to have more severe disease, are almost invariably rheumatoid factor and CCP positive. They are more prone to other extra-articular (meaning outside of the joint) features of rheumatoid, including vasculitis (inflammation of blood vessels) and lung disease. Very occasionally, rheumatoid nodules can develop within the lungs. These are usually asymptomatic (i.e. you would not experience any symptoms from this) but can cause concern to doctors because of uncertainty about the diagnosis and may require additional tests such as a CT scan.

What can we do about nodules?

There is little research in this area. Combination disease-modifying therapies and the biological therapies, in particular rituximab, seem to have reduced the incidence of nodule formation. If micronodules develop while on methotrexate, then the addition of hydroxychloroquine and other disease-modifying drugs, including prednisolone, may reduce their size.?

If nodules are small, they can be ignored. However, if they are subject to repeated trauma, surgical removal is an option. Occasionally, injection of steroid into or just under the nodule can reduce their size.?

References available on request

This article was downloaded from www.nras.org.uk. National Rheumatoid Arthritis Society (NRAS) is a registered charity in England and Wales (1134859) and Scotland (SC039721). A private company limited by guarantee. Registered in England and Wales (7127101).