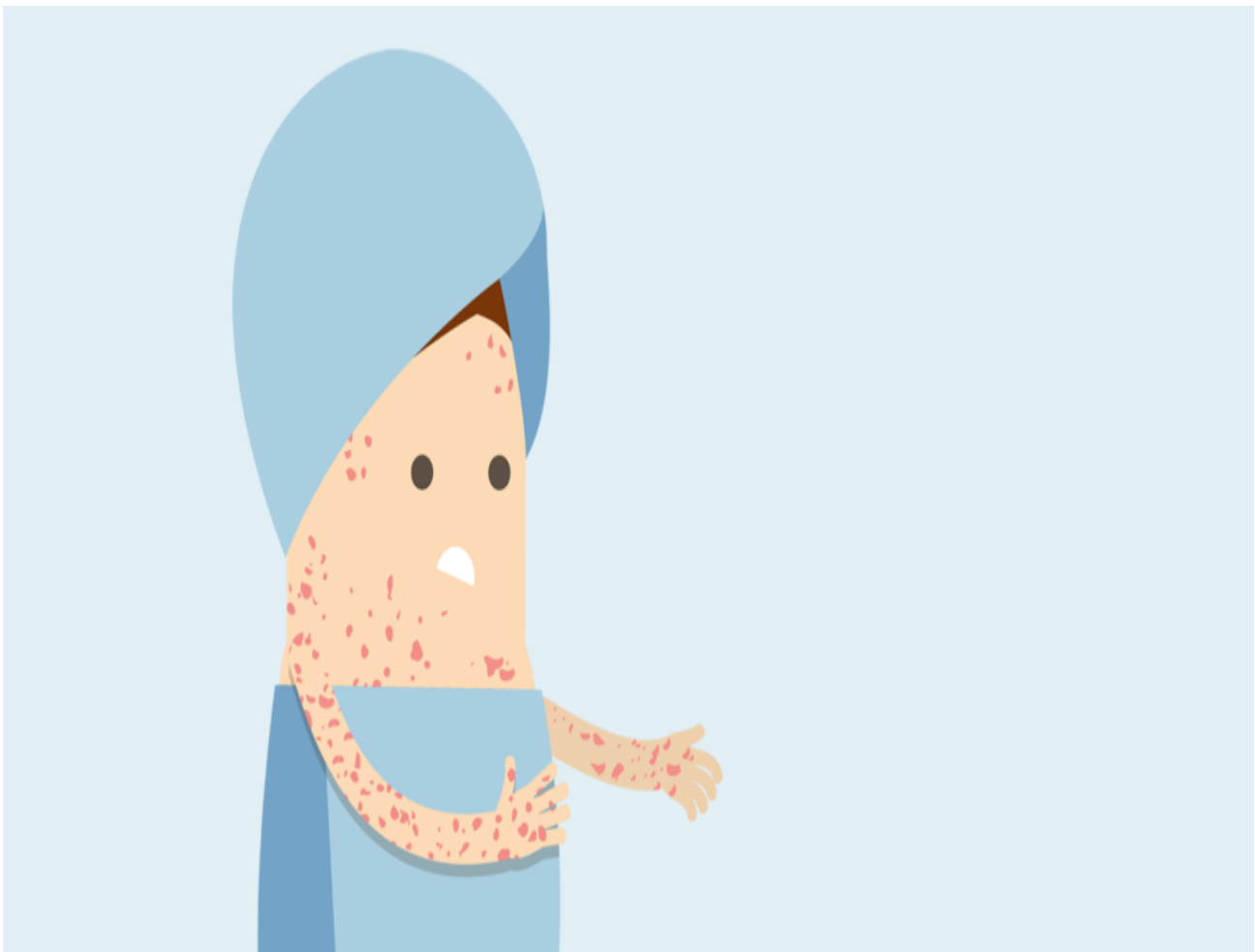


Resource

What is adult-onset Still's disease (AOSD)?

Adult Onset Still's Disease (AOSD) is an auto-immune disease. The condition affects the joints and internal organs and has some symptoms and treatments in common with RA.

[Print](#)



Case History

Ruth was a 24-year-old postgraduate student who had come from the USA to Oxford to do research. She had been fit and well with no serious childhood illnesses and no family history of any significant diseases. She had participated in sport and enjoyed dance. Ruth woke up one morning with a high temperature, a sore throat and muscle pains. Both she and her GP, whom she consulted, considered that she had a bout of flu. She took paracetamol and drank plenty of fluids. By the

mid-afternoon, her temperature had resolved, and she felt somewhat better. This pattern of high fever and pains repeated, and for the next 10 days, Ruth was unable to work. The fever seemed to be worse in the afternoon or evening. Her muscles continued to feel painful and were worse with the fever, and her joints became uncomfortable, particularly her wrists and knees. She also noted a pale pink rash which seemed much worse when she had her fever. Her GP found that she had numerous swollen lymph glands, particularly in her neck and under her arms. Ruth lost her appetite and lost weight. By day 10 of her illness, she was admitted to hospital with a “fever of unknown origin”. In hospital, it was found that she had swollen joints, a high swinging fever and blood tests that were consistent with severe inflammation. The Rheumatology specialists were called, and a diagnosis of Adult-Onset Still’s Disease was made.

Introduction

Adult Onset Still’s Disease (AOSD) is an auto-inflammatory disease. This means that the inflammation is generated by a disturbance in immune function. The immune system generates inflammation, without the usual stimulus to inflammation, such as infection or injury. The condition affects the joints and internal organs. It is usually present before the age of 40 years. Women are slightly more commonly affected than men. There are no known risk factors, and there is usually no family history. Occasionally a virus may trigger the illness; however, a sore throat is also a symptom of the illness, and therefore there may be confusion over whether this is the cause or the start of the illness.

Symptoms of Adult Onset Still’s Disease

The main features of this condition are fever, joint pains and rash. It is not uncommon, though for the arthritis to not be present at the start of the illness. The patient may simply be very unwell with very high levels of inflammation in their blood, and no other cause found. It is for this reason that patients with AOSD often present to the ‘infectious diseases’ department. The fever comes on quickly, usually once a day in the afternoon or evening and then spontaneously resolves, often going below normal. The temperature may be associated with flushing. The rash, which often but not always accompanies the fever is a salmon pink, blotchy, non-itchy rash. It can, however, mimic many other rashes and on occasion may be itchy and appear like raised lumps. It is often on the upper arms, abdomen and thighs. When the patient has a fever, they feel very miserable, with a headache, severe muscle pain and often a very sore throat. Serositis, which is inflammation of the lining of the lungs (pleura), the lining of the heart (pericardium) and lining of the abdominal cavity (peritoneum) may occur. This would account for severe chest pain, particularly when taking in a deep breath. The lymph nodes, which are swollen and tender, are often widespread. This may suggest the possibility of lymphoma (cancer of the lymph nodes). Biopsy of the lymph nodes shows only reactive changes and no evidence of cancer. Other diagnoses which need to be excluded include rare infections and inflammatory bowel disease. If the joint symptoms present early, then it is less likely there will be a diagnostic delay.?

Diagnosing the condition

Blood tests such as ESR and CRP confirm a high level of inflammation. Other rheumatoid arthritis tests, such as rheumatoid factor and anti-CCP antibody, as well as the other auto-antibodies, are all negative. Very often, the full blood count will show a high white blood cell count and platelet count, but there will be anaemia (low haemoglobin). This is because the high level of inflammation

suppresses the manufacture of red blood cells and the utilization of iron in the marrow. In contrast, the ferritin, which is the iron storage protein, will be very high, and this is often used as a diagnostic test. X-rays of the joints in the early stage are very unlikely to show any abnormality. Although joint swelling can be seen on x-ray, ultrasound would be more useful as a test to visualize inflammation of the joints. A chest x-ray may show an enlarged heart due to inflammation of the heart lining and because there may be fluid around the heart, which can also appear in the lung cavity. The spleen, which is essentially a big lymph node, can be enlarged.

Once the diagnosis has been made, treatment needs to be commenced in order to relieve symptoms and suppress inflammation. This is important because it helps the patient to feel better but also so that damage to the joints can be prevented. It is very difficult in the early stages to predict the course of the illness. A third of patients will have a mono-phasic illness. This means that the illness lasts a few months and then fades away with treatment and does not recur. A third of individuals will have a relapsing course with intermittent flare-ups over subsequent years. These flare-ups are often less severe than the first episode. A further third of individuals, however, will have a disease course which lasts a long time. They will require major immuno-suppressant drug therapy for control, and there may be some effect on major organs. The joints that are involved are similar to those affected in rheumatoid arthritis, and once the fevers and rashes have settled it may be difficult to differentiate the rheumatoid “hand” from an AOSD disease “hand”. The wrists are predominately involved as well as the small joints. Occasionally early damage to a large joint such as the hip may occur. This may in part be due to the very high doses of steroids that were used to control the inflammation at the start of the illness (as steroids can cause osteoporosis if used in high doses/for long periods of time).?

There is much research underway to understand the mechanism behind the auto-inflammatory disease and what generates the inflammation. It is known that high levels of the inflammatory proteins interleukin-1 and interleukin-6 are present. The biological agents (monoclonal antibodies to these proteins) such as anakinra and tocilizumab are consequently used increasingly for the treatment of this condition.

Treatments

Early treatment is aimed at controlling the symptoms of fever and arthritis with anti-inflammatory drugs such as ibuprofen, naproxen and even high dose aspirin. These may be prescribed before the definitive diagnosis has been made. Painkillers such as paracetamol, codeine and tramadol may also be helpful. Corticosteroids such as prednisolone are very often used to control inflammation and fever and to improve anaemia. The anaemia that occurs is not responsive to iron supplementation. When steroids are used, they will often be given with other drugs to help to prevent side-effects. These might include protection against stomach ulcers (omeprazole or lansoprazole) and bone protection to prevent osteoporosis (alendronate and calcium). The aim is to use as low a dose of steroid as possible to control the inflammation, but in the early stages, it is often high doses, often intravenously, that is required.

Due to the long-term impact that steroids can have on the body, the disease will also need steroid-sparing medication for control. Methotrexate which is the most commonly used disease-modifying drug in rheumatoid arthritis, is also used in AOSD. Cyclosporine is also sometimes used to prevent and treat a rare complication of AOSD called macrophage activation syndrome (MAS). This rare complication is associated with a precipitous drop in blood count and can potentially be very

serious. Biological therapies that are often used include the anti-TNF agents infliximab and adalimumab and also, tocilizumab and anakinra. Methotrexate is used together with these agents in order to prevent the development of antibodies against these drugs. Once disease control has been achieved, the drugs will be reduced very cautiously. It is usually not possible to predict outlook until at least 1 year after the onset of disease.

For some of these drugs, monitoring, in the form of regular blood tests may be required to check for potential side-effects.

Once the disease is controlled and the individual feels well again, there is no reason why they should not be able to work and function extremely well in everyday life. The steroids may have caused some side effects such as weight gain and mood change, but this will reduce and disappear as the steroid dose is tailored down.

Conclusion

As with all chronic illness, and particularly this disease, which has such an impact when it hits, frustration and low mood may occur and much understanding, support and encouragement will be needed for the patient and their family. Low self-esteem and self-consciousness are not unusual when individuals have put on weight due to the steroids, missed work or education and feel excluded from life. It takes time to “recalibrate” and this is important to recognize. The transition from being a healthy individual to being one who needs to take tablets, attend hospital appointments and have life-adjustments needs to be taken into account.

Further reading

[NRAS article on osteoporosis](#)

[NRAS article on Disease Modifying Anti-Rheumatic Drugs \(DMARDs\)](#)

[Still's disease causes](#)

Updated: 20/05/2019