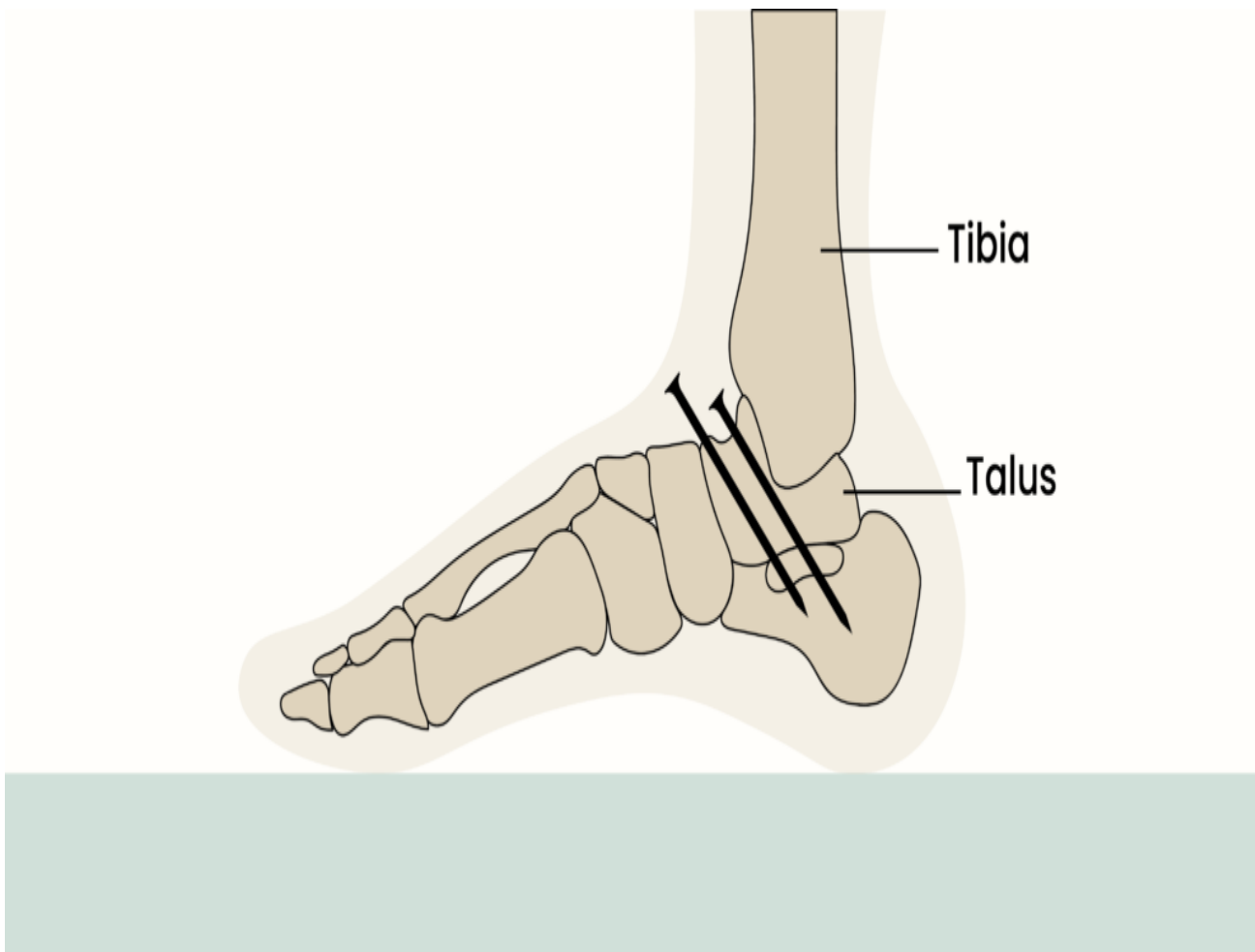


Resource

## Ankle Fusion – A Patient's Perspective

A patient's experience with ankle fusion surgery.

[Print](#)



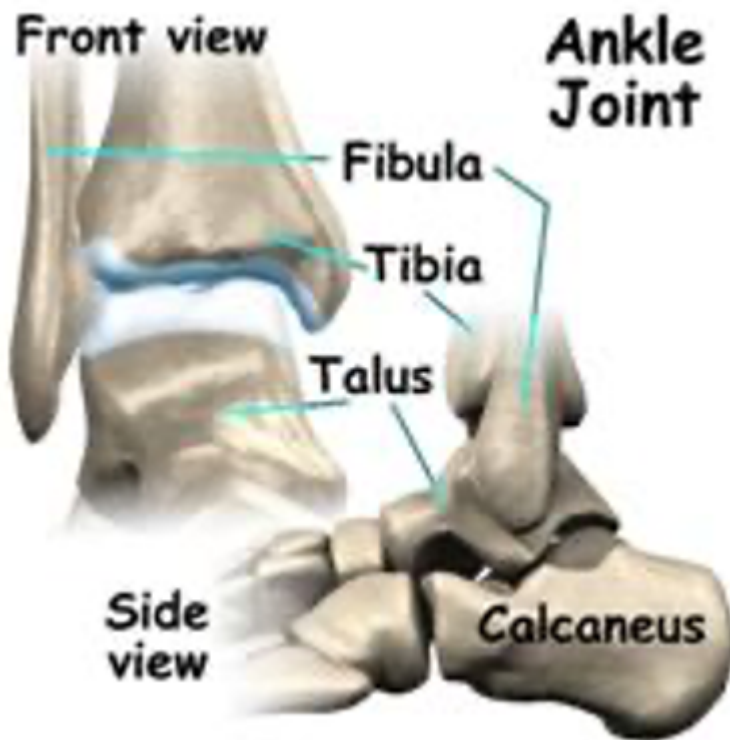08/05/09: Clive Montague

A little about me: I suffer from Adult Still's Disease, a form of chronic rheumatoid arthritis which has over the last years, resulted in the failure of a number of my joints. While knees, shoulder and hips have, during that time, been systematically replaced, I have always tried to put off having an ankle replacement. I don't really know why, but think largely due to a fear of not being able to walk.

However, as my ankle proceeded to become more painful, it became obvious to me that something had to be done, and I couldn't put it off any longer. For some time my ankle has been badly swollen, walking has been difficult, with pains running up the shin and movement severely restricted. With every step, the joint could be heard creaking or groaning, so much so that my wife, who first thought it was the floorboards, only realised it wasn't when she heard it as I walked on a tiled floor. There was some oedema (fluid retention) which didn't help although the swelling would normally reduce a little during the night.

During one of my routine visits to the rheumatologist, he suggested I approach a particular surgeon who specialised in ankles and feet. All seemed to be going fine. I got a letter of referral from my GP and contacted the particular hospital recommended. Then the first problem occurred; the surgeon had retired. Because of this, I then decided to make an appointment to see the surgeon who had carried out all my previous joint operations, for his advice. After an x-ray and examination of the joint, he recommended a particular specialist surgeon and made the necessary onward referral.

The problem was described by the surgeon following a further examination. He told me that the best thing would be an ankle fusion rather than an ankle replacement, due to the poor state of the joint. It is, he said, a relatively simple operation, although he warned that recovery time would be considerably longer than with the previous operations.



The ankle joint is made up of three parts [1]:

1. The lower end of the tibia (shinbone)
2. The fibula (the small bone of the lower leg), and

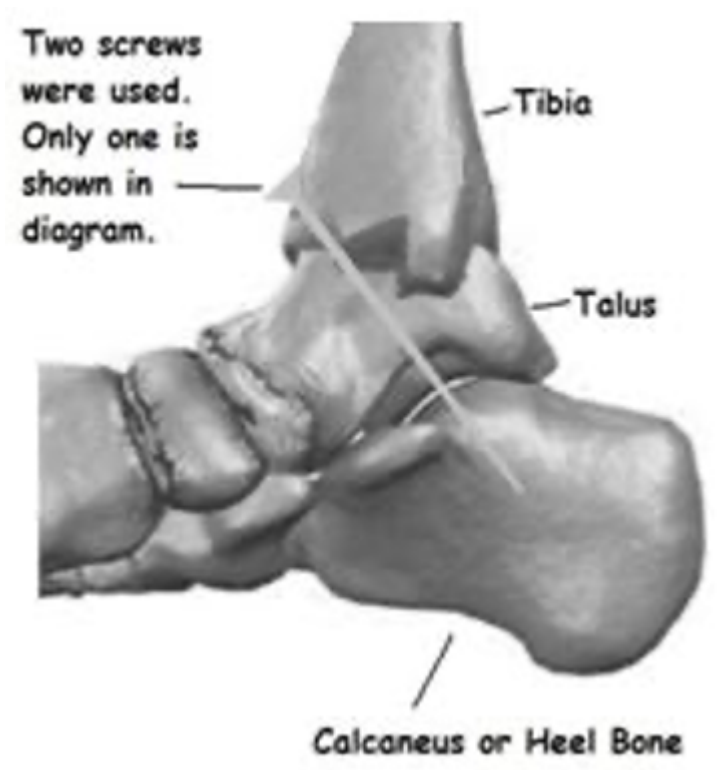
### 3. The talus (the bone that fits into the socket formed by the tibia and fibula).

The talus sits on top of the calcaneus (the heel bone). Where the bones come together inside the joint, they are covered with a slick material called articular cartilage. Articular cartilage is the material that allows the bones to move smoothly against one another in the joints of the body. The cartilage lining is about one-quarter of an inch thick in most major joints, and it can carry body weight, such as in the ankle, hip, or knee joints. It is soft enough to allow for shock absorption but tough enough to last a lifetime, as long as it is not injured. In my case, examination of the x-ray showed that the cartilage had gone, eaten away by the disease. There was no space left, and the bones were virtually moving bone on bone.

Prior to the operation, I was advised by the physiotherapist of what would be needed when I returned home. Living in a house with stairs, I had already had a bed moved downstairs. One of the first problems was that I had two prosthetic hips, the last having been fitted two years before. The physiotherapist said that there was a fear of damage since one had caused some trouble at the time. I borrowed a frame from the Red Cross, to fit around the toilet, and already had a toilet raiser from previous operations. I also borrowed a self-propelled wheelchair and a piece of scaffolding (commonly known as a 'Zimmer frame') to aid walking.

For two weeks one can't put any weight on the operated foot, and due to my other problems, it was suggested that I be kept in hospital for five days while I learnt how to shuffle around using this frame. In the end, I couldn't handle the normal walking frame and the hospital found for me what I believe is called a 'gutter' or 'trough' frame and has padded forms allowing me to rest on my elbows rather than my forearms.

My next visit was to the anaesthetist, who was also a specialist in pain control. After a general health examination, he explained what he intended to do differently to previous operations that I had had. He told me that he would use a general anaesthetic combined with a local anaesthetic in the nerves around the ankle. This allowed him to use a lighter general anaesthetic when putting me under. This method proved much better than during previous operations, where I would be dozy for many hours and often slightly sick. This time I was able to talk on the phone to my wife immediately after arriving back in the ward and then have a cup of tea and piece of toast with no ill effect.



The operation was carried out, and to my knowledge, there were no complications. After removing all traces of cartilage on the surfaces of the joint by cutting away a little of the bone, two screws were put in to hold the joint firmly together. The picture (left) is intended to illustrate how (I don't have copies of the x-ray taken at the time). Following this, the ankle was enclosed in a light, non-weight bearing plaster cast and I spent the next days lying on a bed getting steadily more and more bored. I found there was little pain, and in the first few days what there was easily controlled by Paracetamol. Getting around without putting any weight on the joint was more difficult. My biggest problem was the inability to hop on one foot. My answer to this was literally hanging over the padded frame while sliding on the good foot. Since my forearms and elbows are not the best, this took some getting used to, but where there is a will, there is a way.

After five days I went home to the care of my wife, without whose help I don't know what I could have done. I think she thought she had a new baby albeit rather a heavyweight one. At home, I lay on my bed much of the time, since I needed help to get around and found moving myself in a wheelchair difficult, as I have little strength in my arms. If I sat in the wheelchair, I really needed to prop my leg up on a rest. The Red Cross wouldn't let me have a leg extender for a self-propelled chair, something I now understand, as in the modern house, where rooms are small and doors only just wide enough to get through with care, it would have been impossible. Getting around with a normal chair is still difficult, but not impossible. However, it was necessary until the initial plaster could be removed after 18 days.

At last, the day came for the first soft plaster cast to be removed. The surgeon cut it off and examined the wound, which was healing well. He then went on to say that he had looked into fitting me with an air boot but decided against it because of my other difficulties and was going to fit a lightweight plaster cast, suitable for standing on, and this would be removed after four or five weeks. It appears that an air boot has to be removed at least once every twenty-four hours and then pumped up again.

While I still found it difficult to walk because the plaster presses against the shin bone, which was quite painful, at least I was able to get around with the frame on my own. Up until now, there has been little or no pain in the ankle joint.

Over twelve days, the rubbing on my shin became worse until it broke the skin. Not wanting to risk an infection, I returned to the hospital where the surgeon, after examination, decided to cut back the plaster on the front of the shin. This was carried out and seems to have reduced the rubbing, although the pressure is still there, just lower down the leg. I was told I shouldn't be walking more than was absolutely necessary and to keep the ankle higher than the heart. If you have ever tried this, you will know how uncomfortable it is and that it is nearly impossible to do all the time. What is worse, this has to go on for a further three weeks. The main redeeming feature is that the continual pain has gone.

At last, the day of reckoning came, and the plaster was removed. After a tentative step or two, I am now learning to walk again. One extra, major advantage of having this operation has been the reduction of the Oedema in my good foot, although the operated one swells on and off all the time. This should get better over time. The surgeon told me there was little a physio could do on the ankle but recommended I see one to try to build up the other joints, which had become lazy. This has helped, but whether this improvement will continue once I start living a normal life, who knows? Why did I ever worry?

[1] Much of the description of the joint and the pictures are taken from the Internet website [www.orthogate.org](http://www.orthogate.org) website for the Internet Society of orthopaedic surgery and trauma.

If this information has helped you, please help us by [making a donation](#). Thank you.

## Read more

### [RA Foot health](#)

RA most commonly affects the smaller joints in the hands and feet and something like 90% of people with RA experience pain and problems with their feet, yet all too often the feet can get overlooked by patients and healthcare professionals.

### [Foot Surgery](#)

For most, foot orthotics, medication and good footwear can be enough to manage foot health in RA, but in some cases, surgery may be required, whether it's the removal of painful bunions or more extensive corrective joint surgery.