

Resource

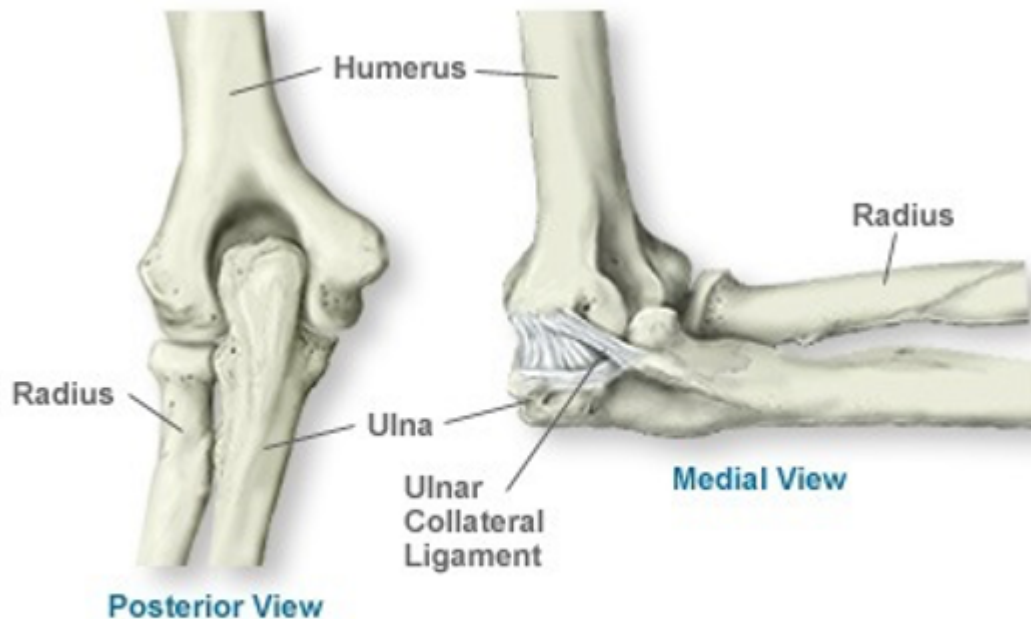## Elbow Surgery

A total elbow replacement is predominantly a procedure which is carried out in patients with longstanding RA. When it is needed, a metal and plastic replacement joint to the elbow can add significant quality of life to the patient.

[Print](#)

The first type of elbow arthritis surgery was carried out by excising the ends of the bones at the joint, either completely or partially, and then covering the remaining bone ends with the patients' own soft tissue. These methods are still used today but are mostly reserved for situations where the initially inserted metal and plastic replacements had to be removed, most frequently because of persistent infection.

The risks and benefits of elbow replacement



**Figure 1: Elbow joint diagram**

The types of joint replacement which are currently in use date from around the 1970s. The elbow joint

is a hinge between the upper arm (humerus) and the forearm (ulna), which is held together with ligaments, as seen in fig 1. Due to a relatively smaller amount of bone found at the elbow joint (compared with hip and knees) and ligament damage that can occur due to severe rheumatoid arthritis degenerative disease, the elbow replacement joints do not last as long as hip, knee or shoulder joint replacements.

In my experience, however, most of the patients who come to see me want to consider a joint replacement because the range of movement in the elbow joint has gradually been severely reduced so they can no longer get their hand to their mouth or the elbow joint are now so painful that useful function is impossible. During, the last decade, due to improved medical treatment severely painful and destroyed joints have become less common and total elbow replacement is, in my experience, performed less often than it used to be. Joint replacement surgery of the elbow, if successful, is very good in terms of reducing the pain within the first week, but is also good in improving the ability to bend the elbow beyond what was previously possible. An artificial elbow joint does not guarantee any improved straightening of the elbow, however, for most patients that is often a less important problem.

There are, in principle, three types of artificial elbow joint replacements available, depending on how securely the two components locked together, called constrained, semi- and non-constrained. The better the ligaments are functioning, the less stability is required from the joint replacement, and it is less likely to come loose due to twisting of the implant inserted into the bone. However, if the disease has destroyed the ligaments or there have been previous surgeries, it may be necessary to use an implant type where the two components are securely locked together to prevent the joint from dislocating. Generally, for a first time total elbow replacement, a semi or unconstrained implant is used, (see figures 2&3). Generally, if there are strong and working ligaments around the elbow, the joint replacement will work longer before it eventually comes loose. The result following elbow replacement varies greatly and has been reported in some cases with certain implants to have a loosening of up to 50% within a few years and in other cases with other implants to be successful for over 15 years for many patients with osteoarthritis or rheumatoid arthritis.



## The surgery

If the patient and surgeon agree that a total joint replacement of the elbow would be beneficial to the

patient despite the inherent risks, then most frequently these procedures are carried out as an inpatient procedure under a general anaesthetic. The procedure takes approximately two hours, during which the blood supply to the arm is stopped. The most significant risk is a nerve injury to the ulnar nerve (which governs some of the tendons and muscles of the hand) and a fracture to the bones around the elbow. Both of these risks are less than 1%. After surgery, there is a risk of developing an infection in about 1% of cases, which may require antibiotic treatment and in rare cases a removal of the implanted joint replacement.

Under normal circumstances, the patient would be allowed to start moving the elbow joint the following day after surgery and will stay in hospital for less than one week afterwards, the length of which will depend on how much pain there is following surgery and how the progress is with rehabilitation. Normally within the first week, the patient should be able to reach their mouth with the operated hand. Because of the ligament and tendon surgery, there is a restriction in the amount of force they are allowed to exert in extension (straightening of the elbow) for the first six weeks, but after that normal activity can usually be resumed. For patients who use a walking stick or crutch in the operated arm, this poses potential future problems, as replaced elbow joints have been seen to come loose more rapidly if the elbow joints are made to take up the full body weight on crutches. This risk has to be considered prior to surgery, and if any necessary lower limb surgery, hip and/or knee surgery is, therefore, best off being carried out before elbow surgery is performed.

## Conclusion

In my experience, for patients who have significant pain and functional disabilities, particularly if both elbows are affected, a metal and plastic replacement joint to the elbow can add significant quality of life to the patient. However, every potential patient for this type of surgery should appreciate that there is a higher risk of the implant coming loose in the elbow than is seen in hip, knee or shoulder surgery, particularly if the patient is using a walking stick or crutch in the affected arm. Therefore a somewhat more cautious approach than that adopted for hip replacement surgery is advisable. However, on the whole, elbow joint replacement surgery can be an excellent operation in the carefully selected patient group, and most complications can be successfully treated even if the first joint replacement becomes loose and has to be revised, as the case study below testifies. Due to its less frequent use, this operation is probably best carried out by surgeons who specialise in upper limb surgery.

## Case study

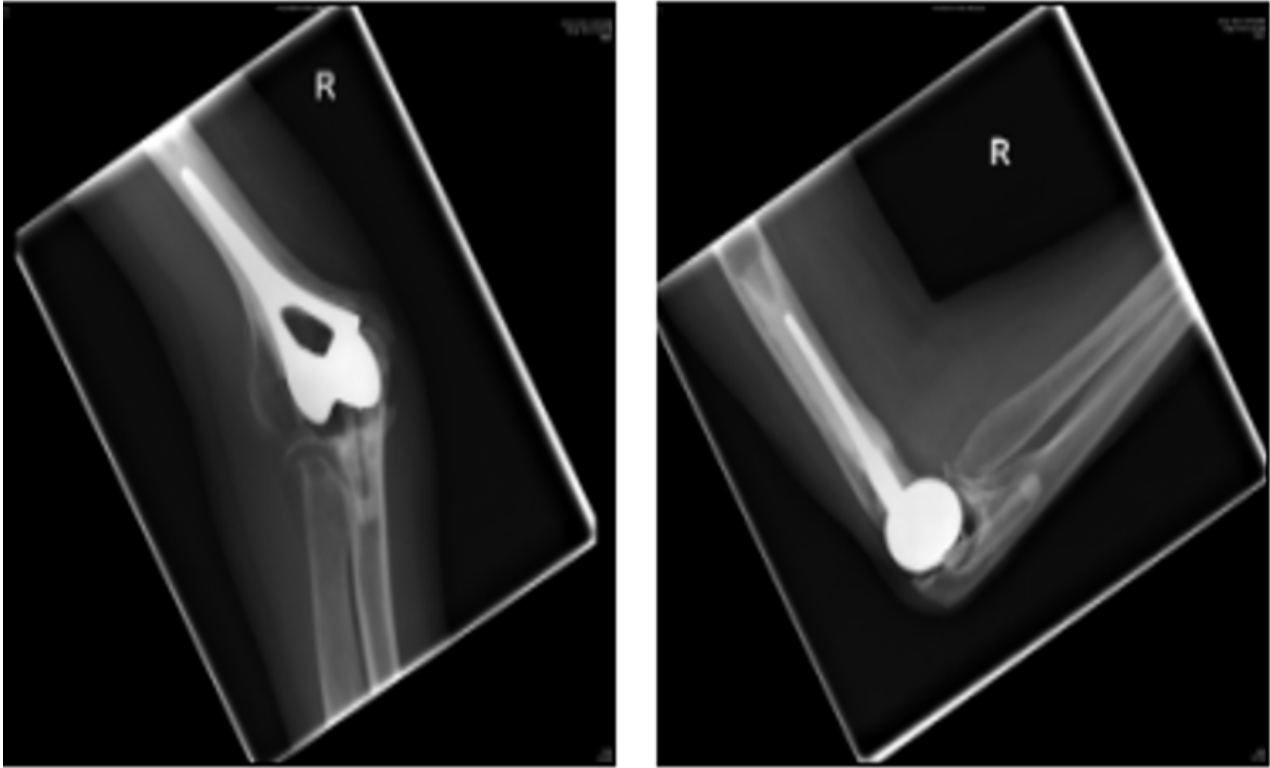
Below is an account of one of my previous patients in her own words. She has kindly allowed us to reproduce the follow-up x-rays 9 years after the last operation.

Jean writes:

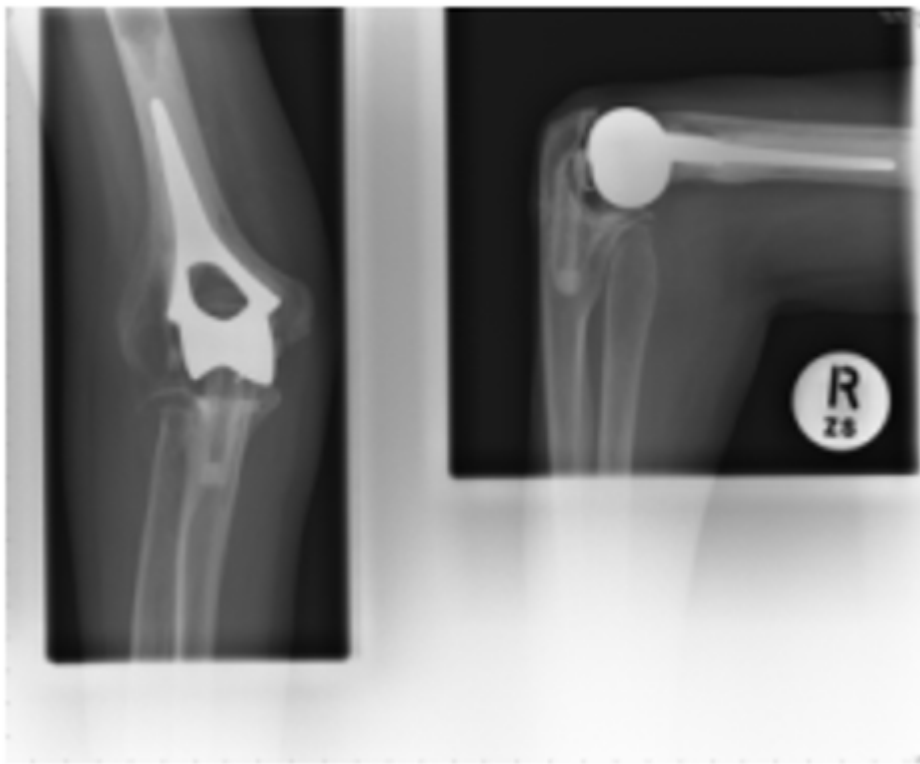
"I had my right elbow replaced (in 1992) as it was too painful to move. I was in hospital for a few days, followed by several weeks of intensive physiotherapy exercises. I was able to use my arm, to varying degrees, a few days after the operation and within a few months was using the arm normally and without giving it much thought. Because of the type of replacement used at that time and probably helped by an accident in late 1995, when my elbow took quite a knock, the joint had eventually become loose and moved, causing pain. It was replaced again in the early part of 2000 and has been entirely successful. In both cases, my only limitations in using the arm are those imposed by having rheumatoid arthritis in my hands, wrists and shoulders. My elbow joint is free from pain, strong and stable, with only a thin scar which no-one has ever noticed. The replacement will not allow my arm to

lock into a completely straight line, but I have never had any need for my arm to be in that position. I can still carry a briefcase or bag and bend my arm to touch my shoulders and the back of my head and neck. My advice to anyone needing an elbow replacement is to:

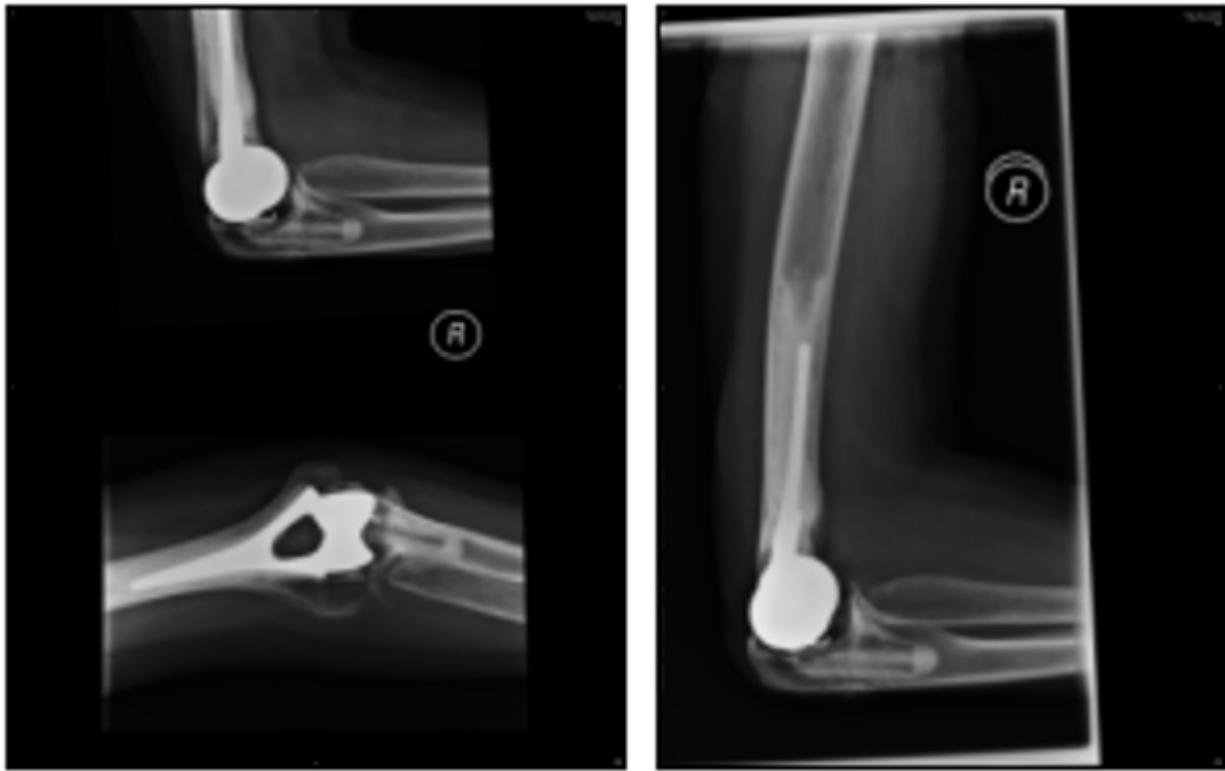- choose a specialist as opposed to a general orthopaedic surgeon
- persevere with the physiotherapy exercises in order to get the elbow moving through its full range
- ask the surgeon at the final out-patients visit if there is anything you shouldn't do
- not be frightened to use it



Above: 2006 x-rays (left is front view and right is side view of the elbow)



Above: 2007 x-rays (left is front view and right is side view of the elbow)



Above: 2009 x-rays (left is side & front view and right is side view of the elbow)

These x-rays show the right elbow joint from the front (AP), and side (lat) after the original implant was replaced in 2000 after it came loose. As shown in the x-rays over the subsequent 9 years, there has been no loosening, but the patient will continue to have yearly follow-ups.

References available on request

If this information has helped you, please help us by [making a donation](#). Thank you.

This article was downloaded from [www.nras.org.uk](http://www.nras.org.uk). National Rheumatoid Arthritis Society (NRAS) is a registered charity in England and Wales (1134859) and Scotland (SC039721). A private company limited by guarantee. Registered in England and Wales (7127101).